

Purpose

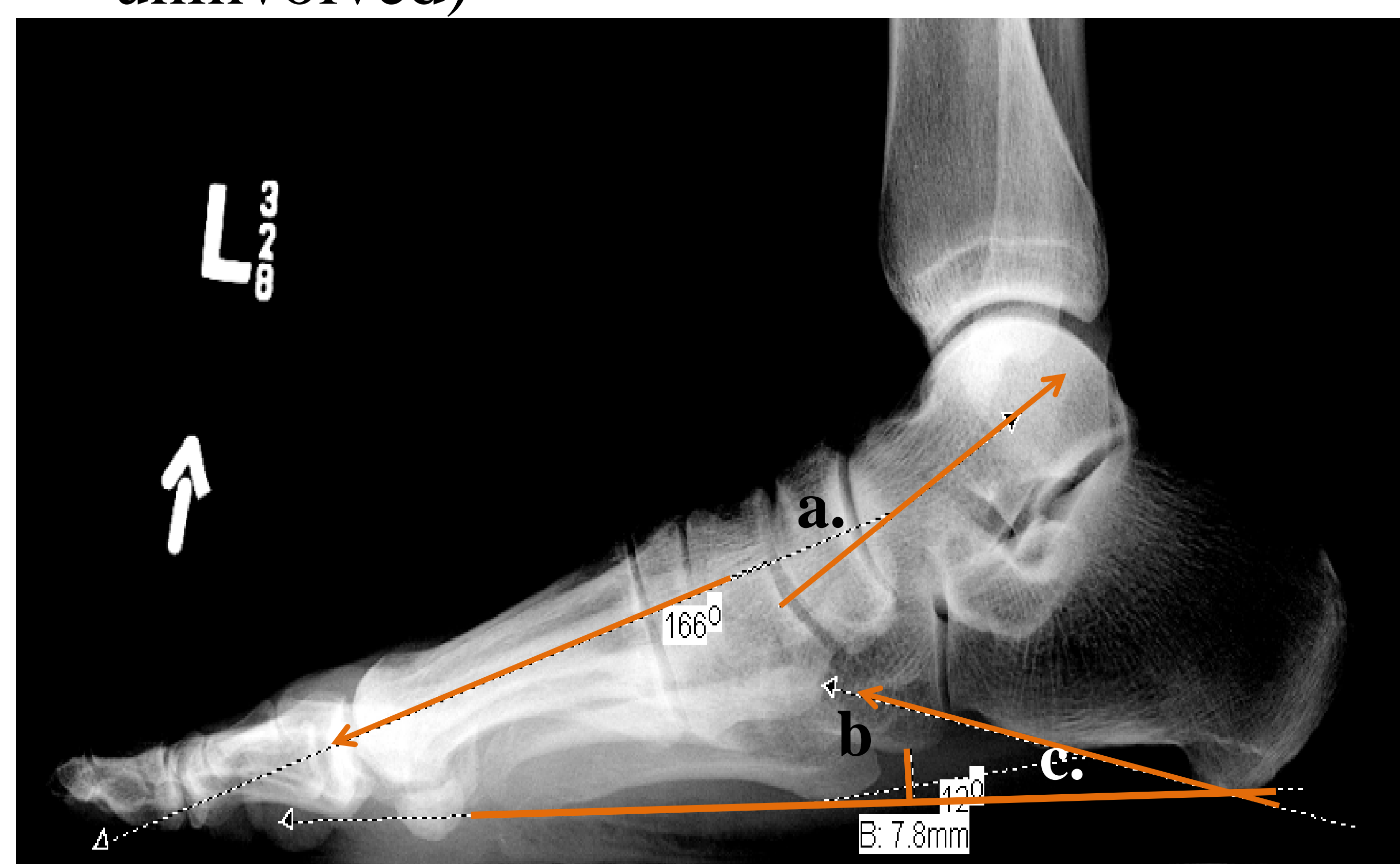
The purpose of this study was to follow patients with and without acute neuropathic Charcot arthropathy (NCA) for up to 2 years to examine the magnitude and timing of foot alignment changes.

Subjects

- Subjects with NCA
 - 15 for one year
 - 8 for two years
- Subjects with diabetes and peripheral neuropathy without NCA
 - 19 for one year
 - 5 for two years

Methods

- Bilateral, weightbearing foot radiographs at
 - ❖ baseline for all groups
 - ❖ 6 months for the NCA group
 - ❖ year one and two for the NCA and DMPN groups.
- Measures: Meary's angle, cuboid height, and calcaneal pitch
- Analysis: Repeated measures analysis of variance group x time x feet (involved and uninvolved)



a. Meary's Angle, b. Cuboid Height, c. Calcaneal Pitch

Results: Meary's Angle

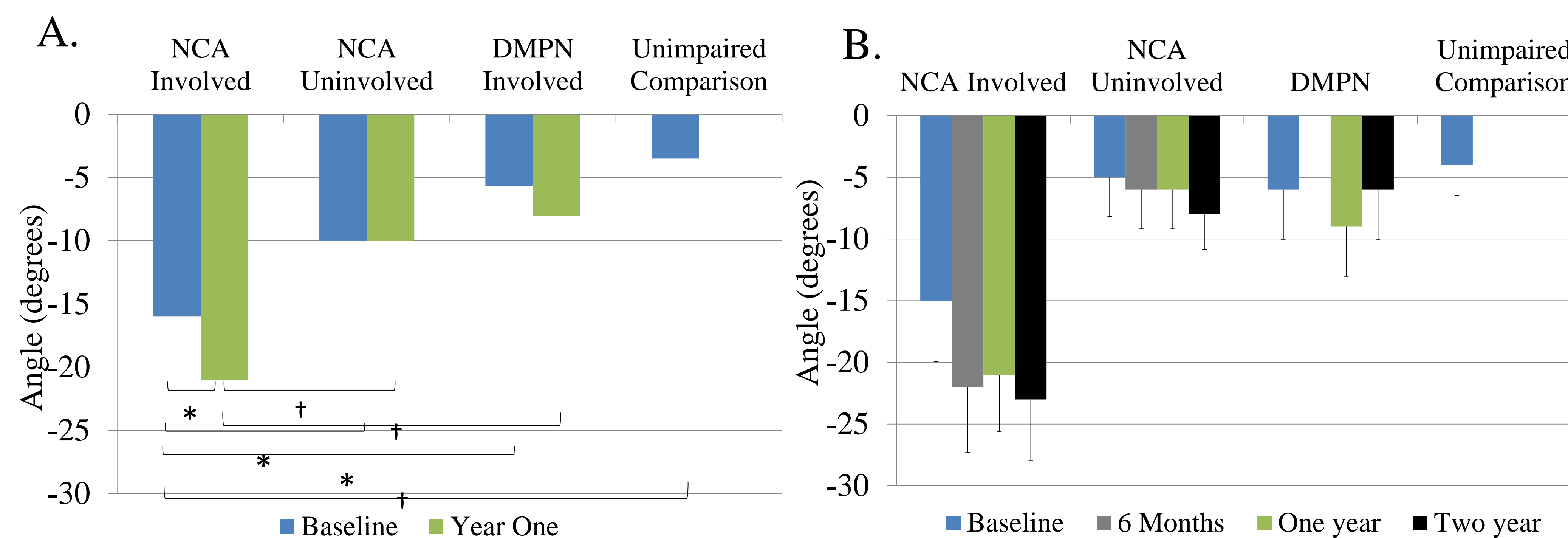


Figure A: Meary's Angle worsens from baseline to one year on NCA involved side. B. Little change in Meary's angle during final 18 months on the NCA involved side (mean with standard error of the measure bars). * $p \leq .04$, † $p \leq .01$

Results: Cuboid Height

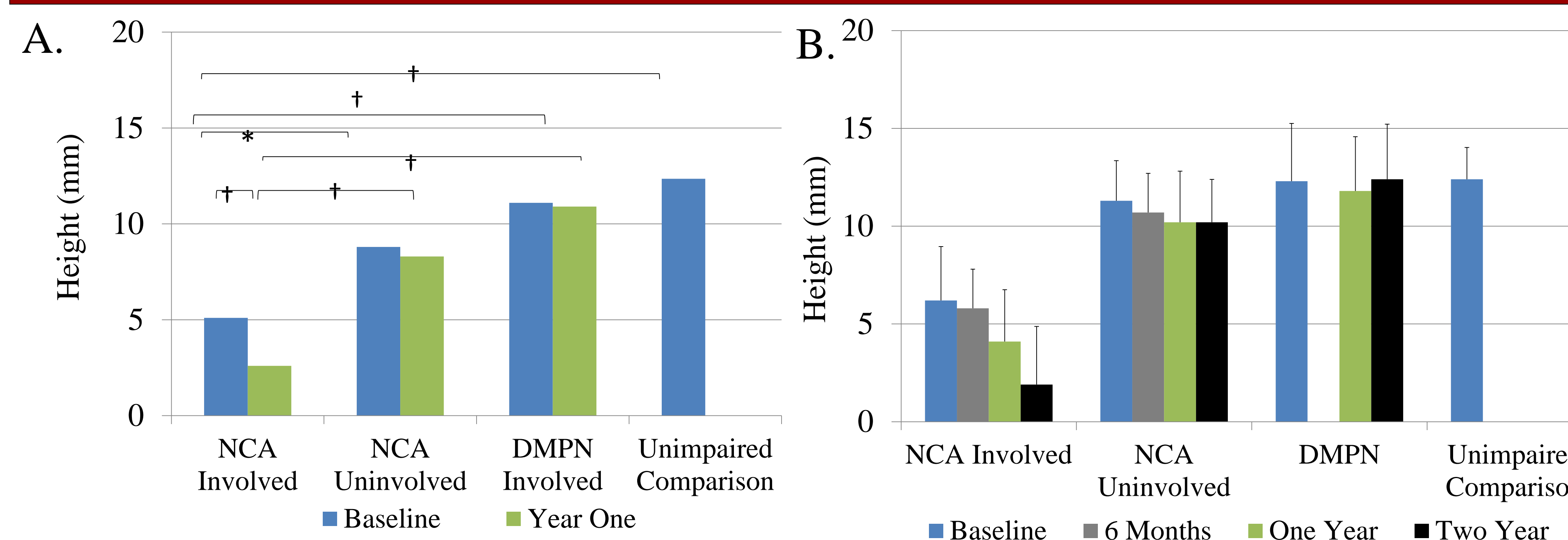


Figure A: Cuboid height worsens from baseline to one year on NCA involved side B. Largest change in cuboid height is during the final 18 months on the NCA involved side (mean with standard error of the measure bars). * $p \leq .04$, † $p \leq .01$

Results: Calcaneal Pitch

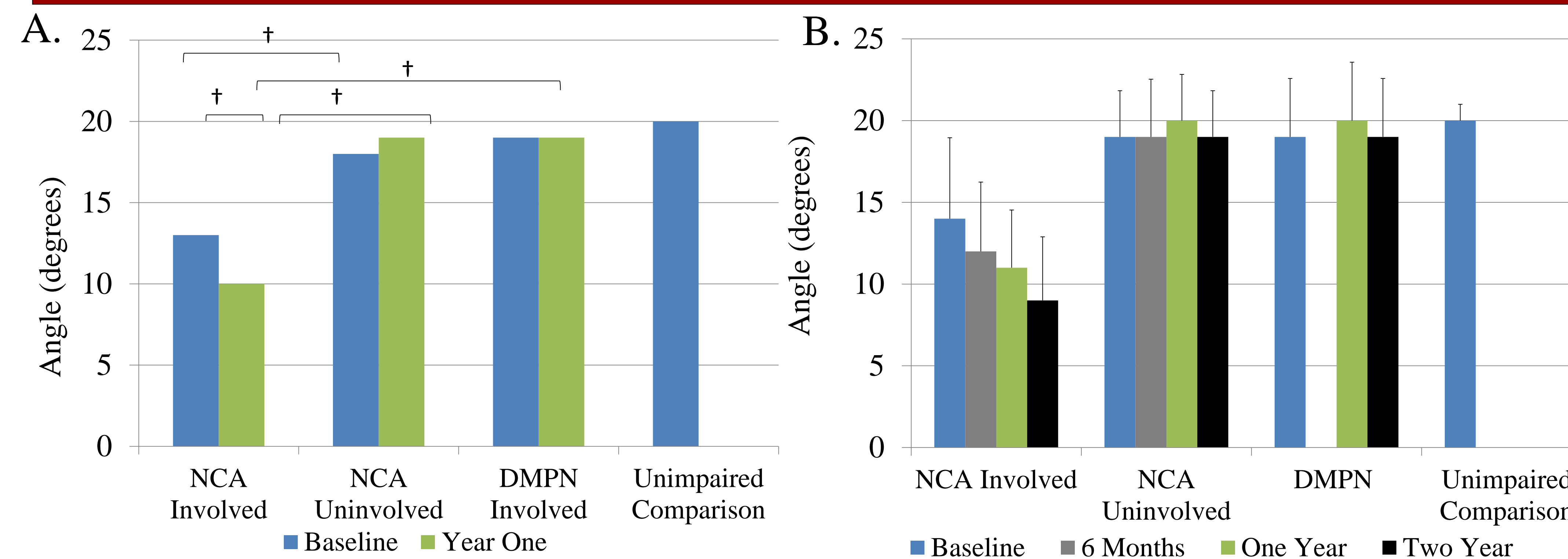


Figure A: Calcaneal pitch worsens from baseline and one year on NCA involved side B. Continued decline throughout the two year follow up on NCA involved side (mean with standard error of the measure bars). * $p \leq .04$, † $p \leq .01$

Conclusions

- At Baseline NCA involved foot alignment was worse than DMPN and unimpaired comparison feet.
- Longitudinal alignment measures demonstrate “creep” with progressive foot deformity over the first and second year.
- Six-month-interval data suggest medial column of the foot changes precede lateral column changes of the foot.

Clinical Relevance

- Repeat radiographic alignment measures provide useful information about the stability of foot alignment and improves our traditional understanding of the natural history of NCA.
- Worsening foot alignment indicates the need for more aggressive intervention (conservative bracing or surgical fixation) to prevent limb threatening complications from severe deformity and joint instability.